

# Identifying Best Practices for Orthopaedic Treatment of Pediatric Gunshot Injuries: A Systematic Review

Alex Villegas, BS; Amanda T. Whitaker, MD  
UC Davis Health Department of Orthopaedic Surgery, Sacramento, CA

## Introduction

- Firearm injuries in children are an increasing problem in the United States
- Despite the broad literature on adult treatment, studies in the pediatric population are limited
- This systematic review aims to identify evidence-based orthopaedic treatments for pediatric gunshot injuries

## Design/Sample

- PRISMA guidelines were used to search Cochrane, PubMed, Scopus, and Google Scholar to identify studies from inception to October 2022
- Inclusion criteria involved studies discussing treatment of firearm injuries
- Exclusion criteria encompassed studies not discussing pediatric patients
- Location of injury, quantity of fractures, treatment received, and complications were recorded

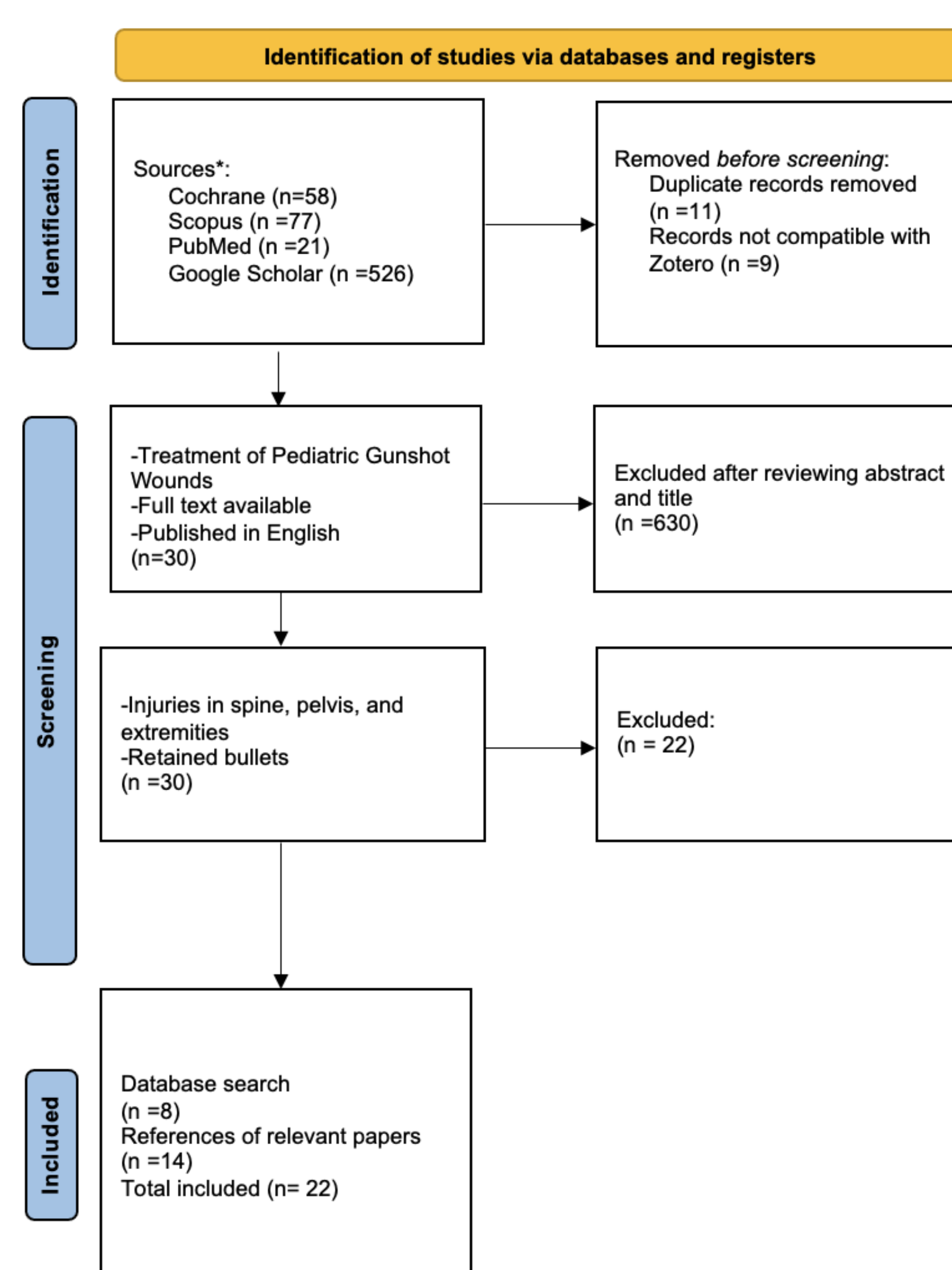


Figure 1: PRISMA diagram illustrating the search strategy for this systematic review

## Results

- A total of 52,414 cases were evaluated in this review with 38% sustaining injuries to the extremities
- Lower extremity injuries were the most common (37%)
- 22% of firearm injuries resulted in fractures and 79% had soft tissue injury
- Most fractures were in the lower extremity (51%)
- 76% of injuries were caused by handguns followed by 11% shotguns, 7% airguns, and 2% rifles
- Injuries were due to 63% assault, 33% accidental, 3% suicide, and 1% law enforcement
- 17% of patients were treated in the OR and 82% in the ED
- Approximately 14% of patients had bullets removed
- 36% of patients had prior police reports, gun injuries, or significant trauma/legal event
- Complications included 11% nerve injury, 8% soft tissue infection, 6% vascular injury, and 4% deep infection
- Immediate loss to follow-up was 43%

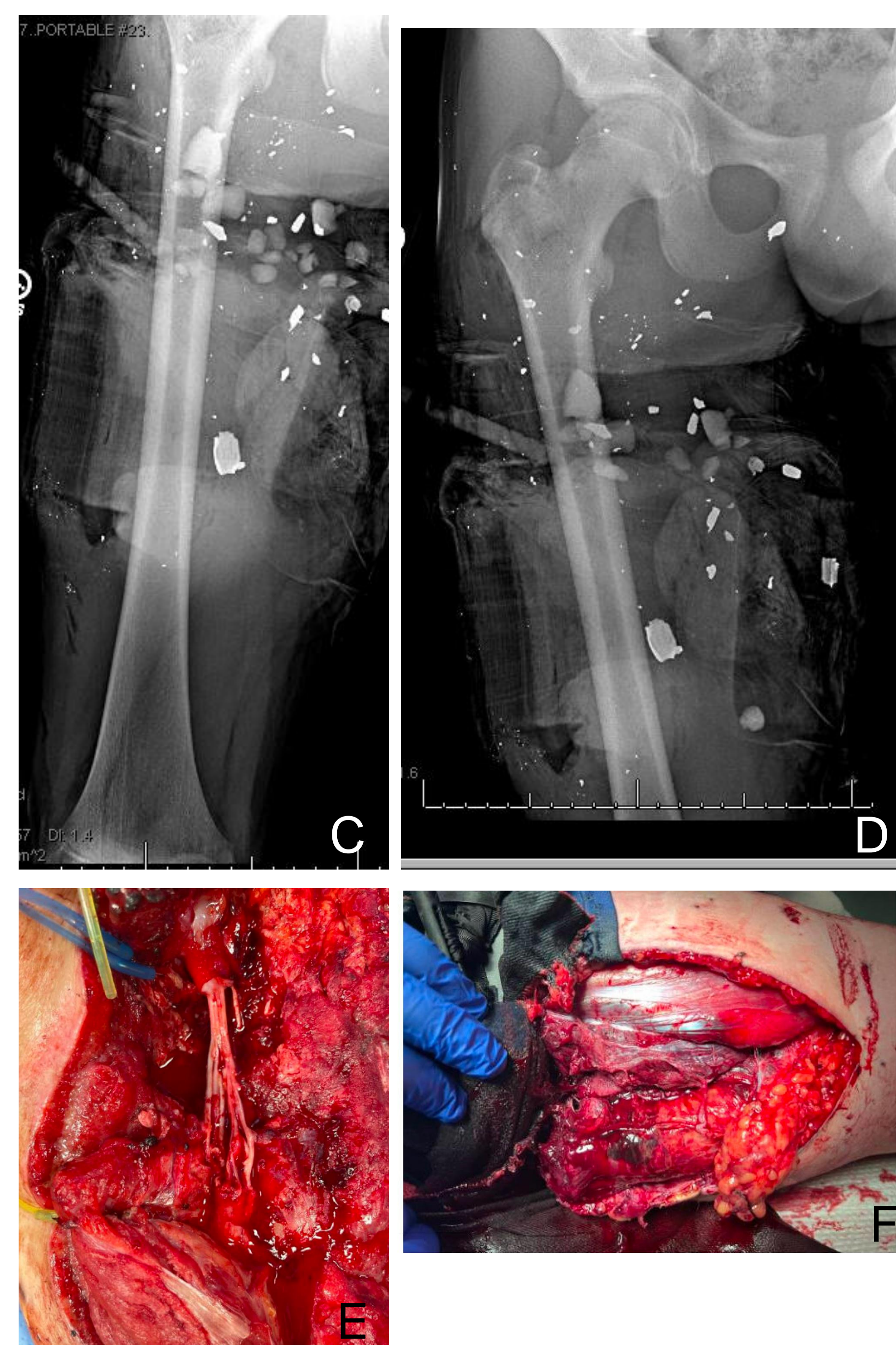


Image C-F: 14 y.o. with an accidental injury from an AR-15




Image A-B: 15 y.o. with rifle injury and sciatic nerve transection, treated with split-thickness skin graft

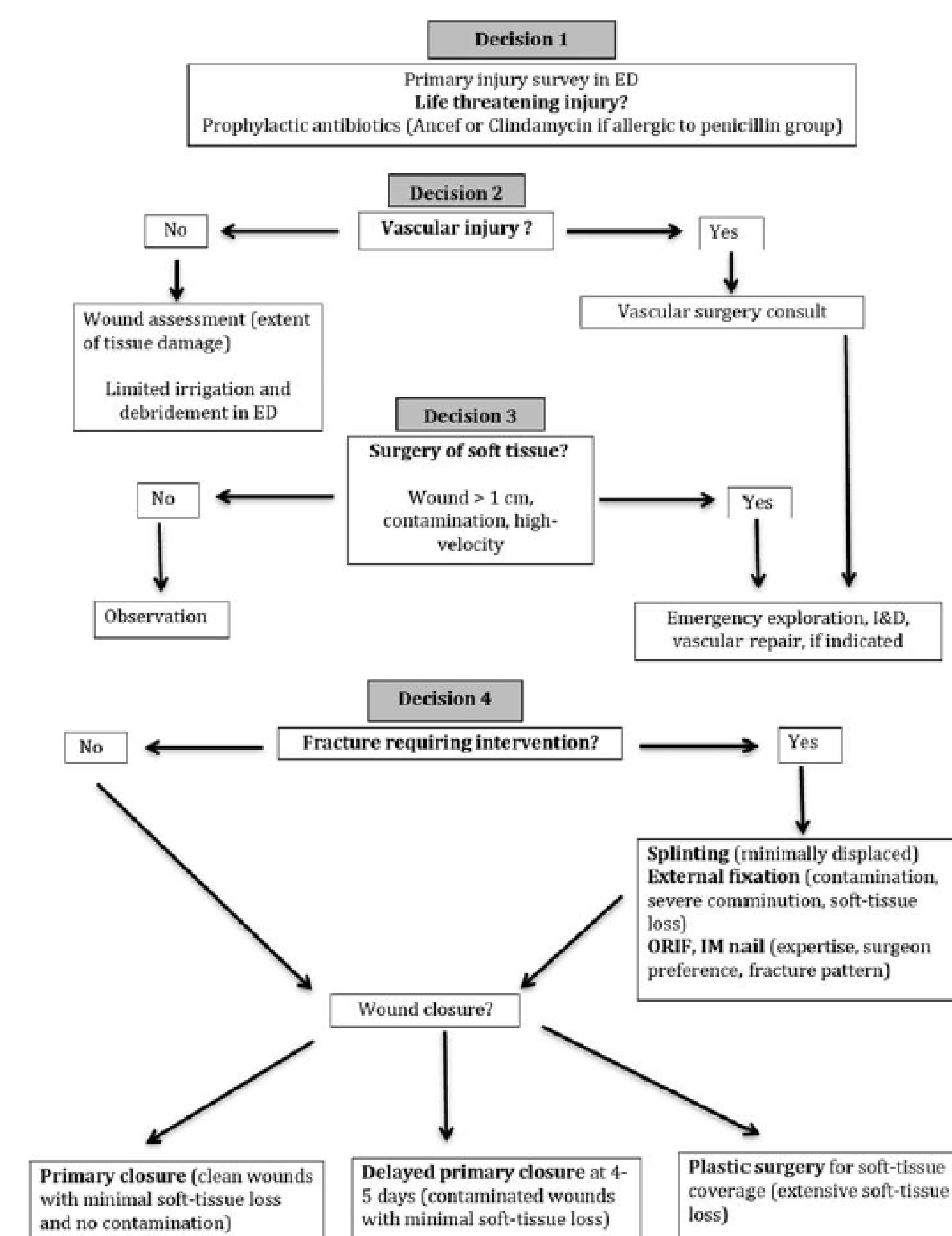


Figure 2: Treatment algorithm for fractures caused by gunshots. Adapted from Naranje et al. Copyrights permission obtained.

Study	Sample Size	Injury Site	Primary Weapon Reported	Level of Evidence
Allareddy et al.	14831	Multiple regions	Not specified	IV
Arslan et al.	22	Extremities	Shotgun	IV
Barlow et al.	108	Multiple regions	Handgun	IV
Blumberg et al.	34494	Extremity	Not specified	III
Dabash et al.	10	Extremities	Handgun	IV
Davis et al.	740	Multiple regions	Not specified	IV
Heins et al.	131	Multiple regions	Not specified	IV
Letts et al.	54	Extremities	Handgun	IV
Lieu et al.	61	Extremities	Not specified	IV
Mazotas et al.	107	Multiple regions	Not specified	IV
Naranje et al.	49	Extremities	Handgun	IV
Newgard et al.	505	Multiple regions	Airgun	IV
Ordog et al.	255	Multiple regions	Handgun	IV
Perkins et al.	46	Extremities	Handgun	IV
Scribano et al.	166	Multiple regions	Airgun	IV
Senger et al.	194	Multiple regions	Rifle	IV
Stricker et al.	51	Extremities	Handgun	IV
Stucky et al.	85	Extremities	Handgun	IV
Valentine et al.	90	Multiple regions	Handgun	IV
Veenstra et al.	303	Multiple regions	Airgun	IV
Victoroff et al.	75	Extremities	Handgun	IV
Washington et al.	37	Extremities	Handgun	II

Figure 3: Studies included in this systematic review

## Conclusions/Further Study

- Initial management of gunshot wounds in the pediatric population consists of a thorough neurovascular exam and assessing fracture stabilization (Figure 2)
- Vascular status and soft tissue contamination often determine need for surgery
- Most stable fractures can be treated with oral antibiotics and splinting/casting
- Social workers need to be involved before, during, and after treatment
- Retained bullets can cause lead poisoning
- Laws have an impact on gun violence

## Acknowledgements

Thank you to my mentor Dr. Whitaker, Dr. Leshikar for her image contributions, and the University of California, Davis School of Medicine Medical Student Research Fellowship (MSRF)